

Stroke

ESO.org

Csiba László

csiba@dote.hu

Global mortality

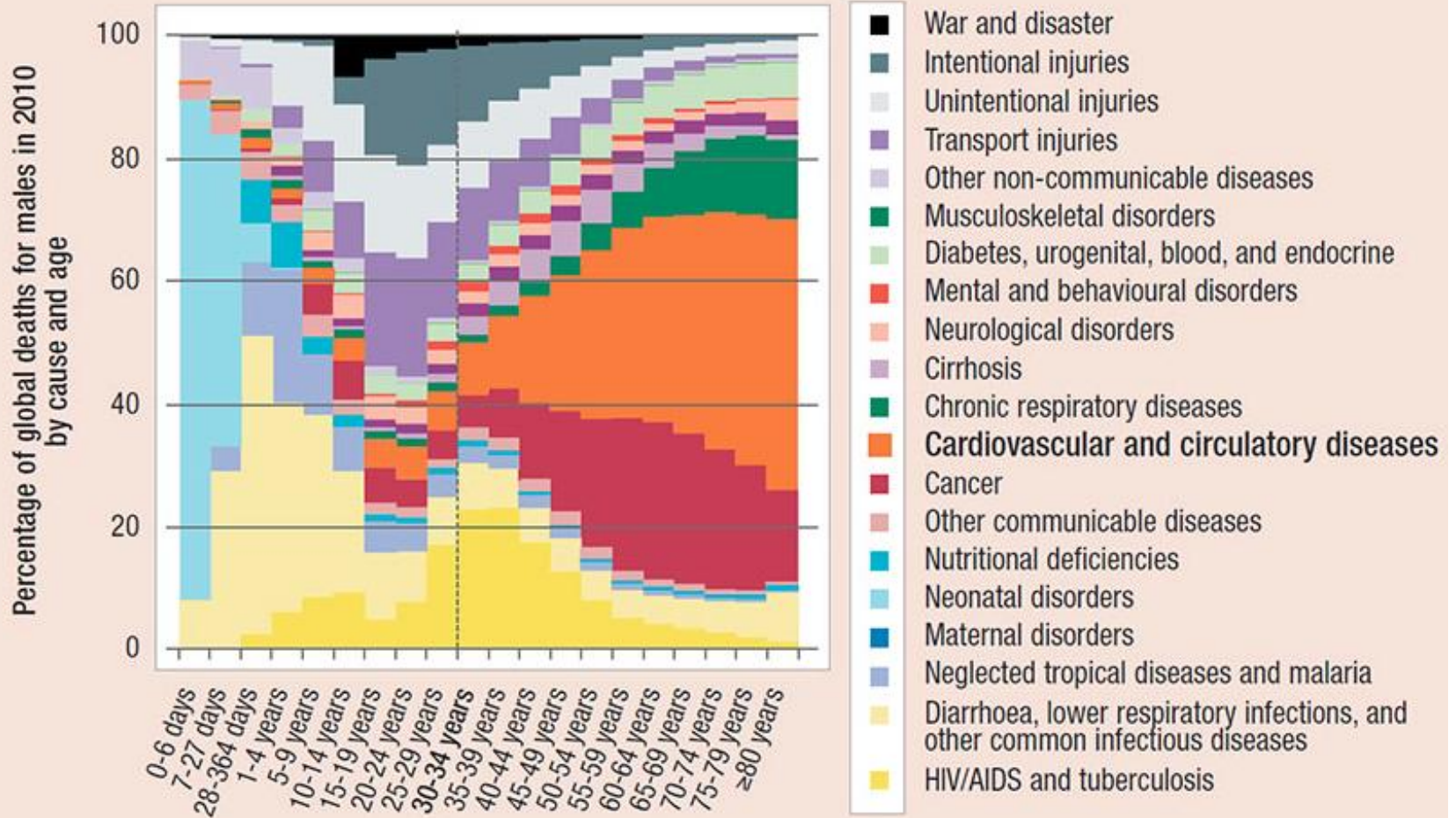
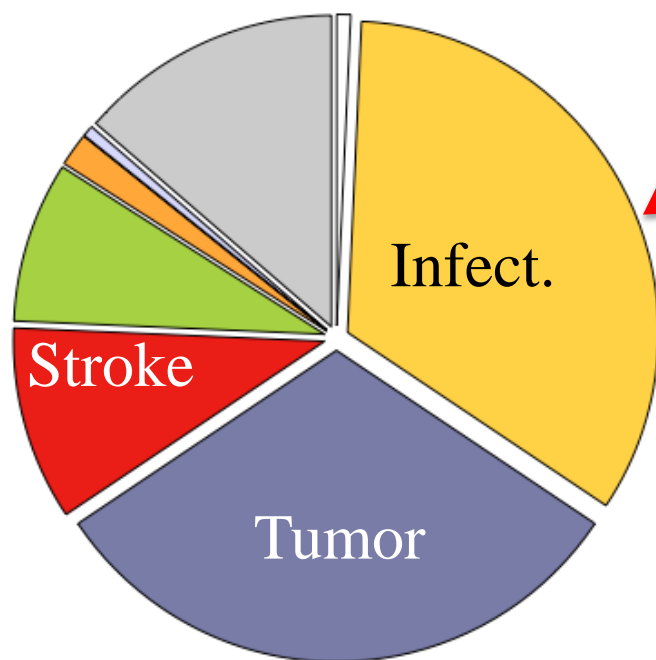


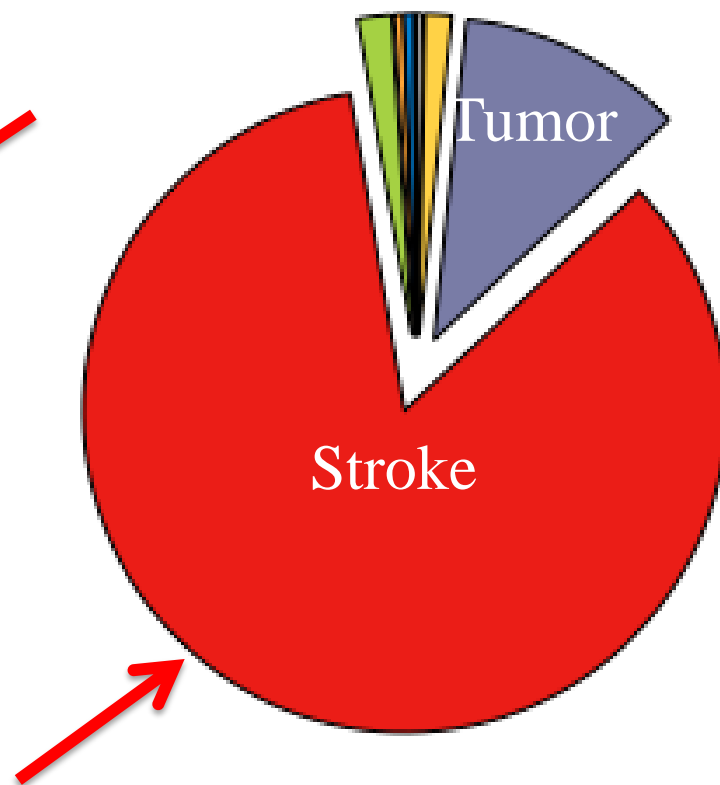
Figure 1. Percentage of global deaths for males in 2010 by cause and age according to the Global Burden of Diseases, Injuries, and Risk Factors Study 2010 (GBD 2010). (1)

Cause of death—Dept. of Neurology?

1938-1950



1990-2002



Normal lifestyle

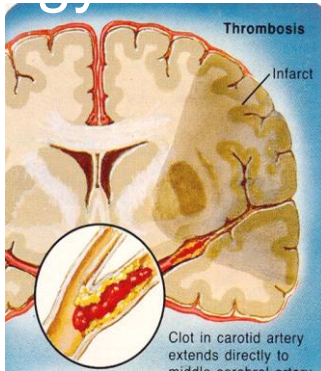


After MI **70-80%**

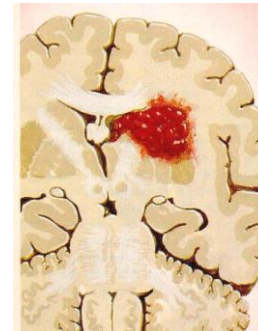
After stroke
10%

Differential diagnosis---CT/MRI!!!

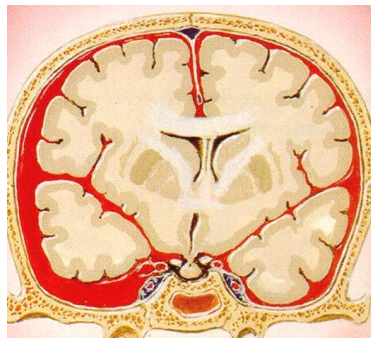
ischemia 80%



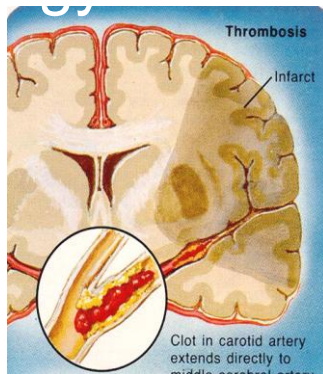
sp. Hemorrhage 10-15%



Subarachnoidal bleeding

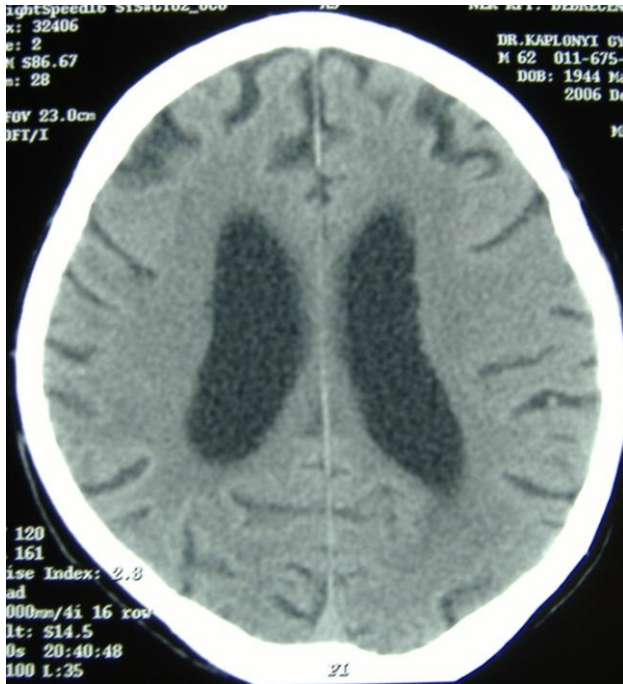

ischemia 80%

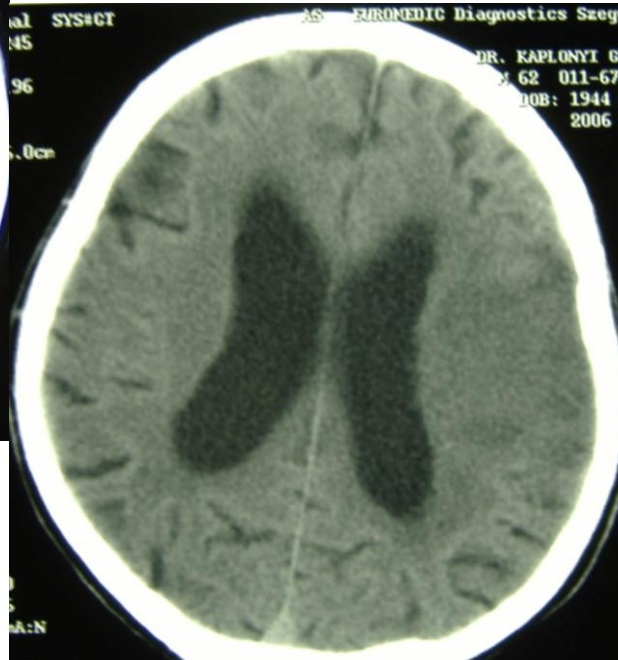


CT

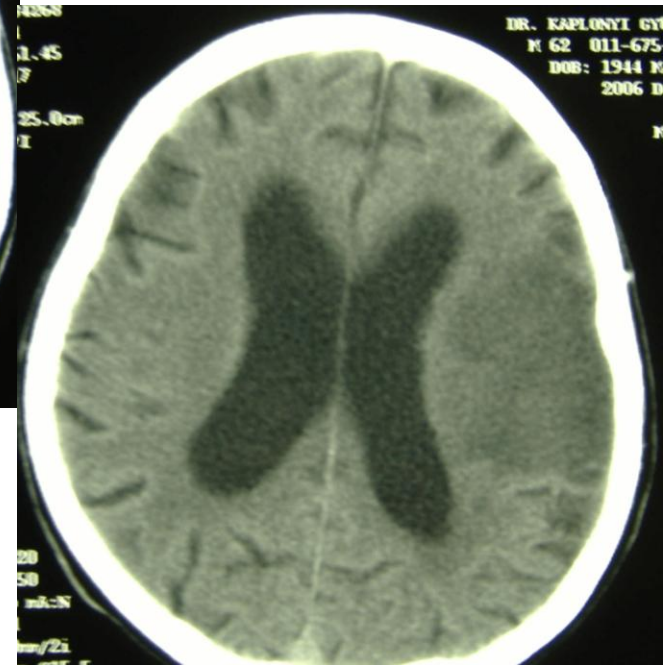
62 yrs stroke at admission



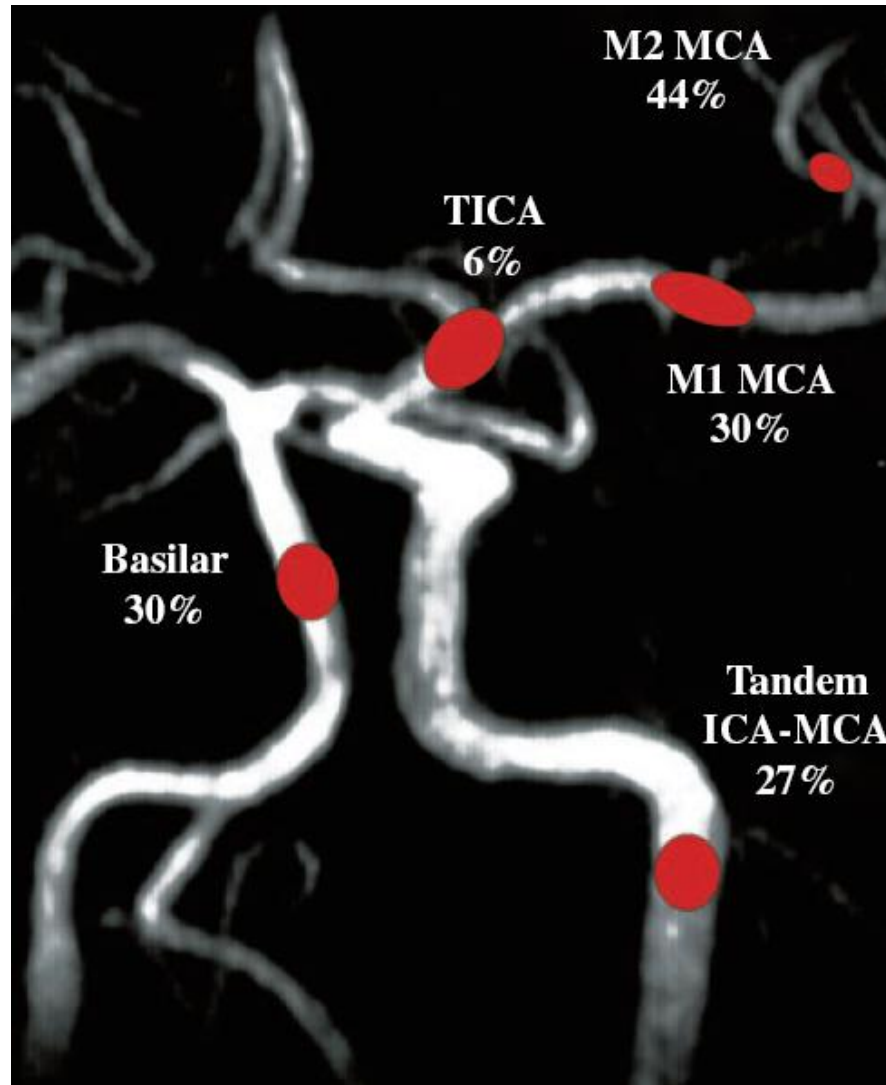
One day later



2 days later




Large vessel occluded? Less chance for successful intravenous lysis..



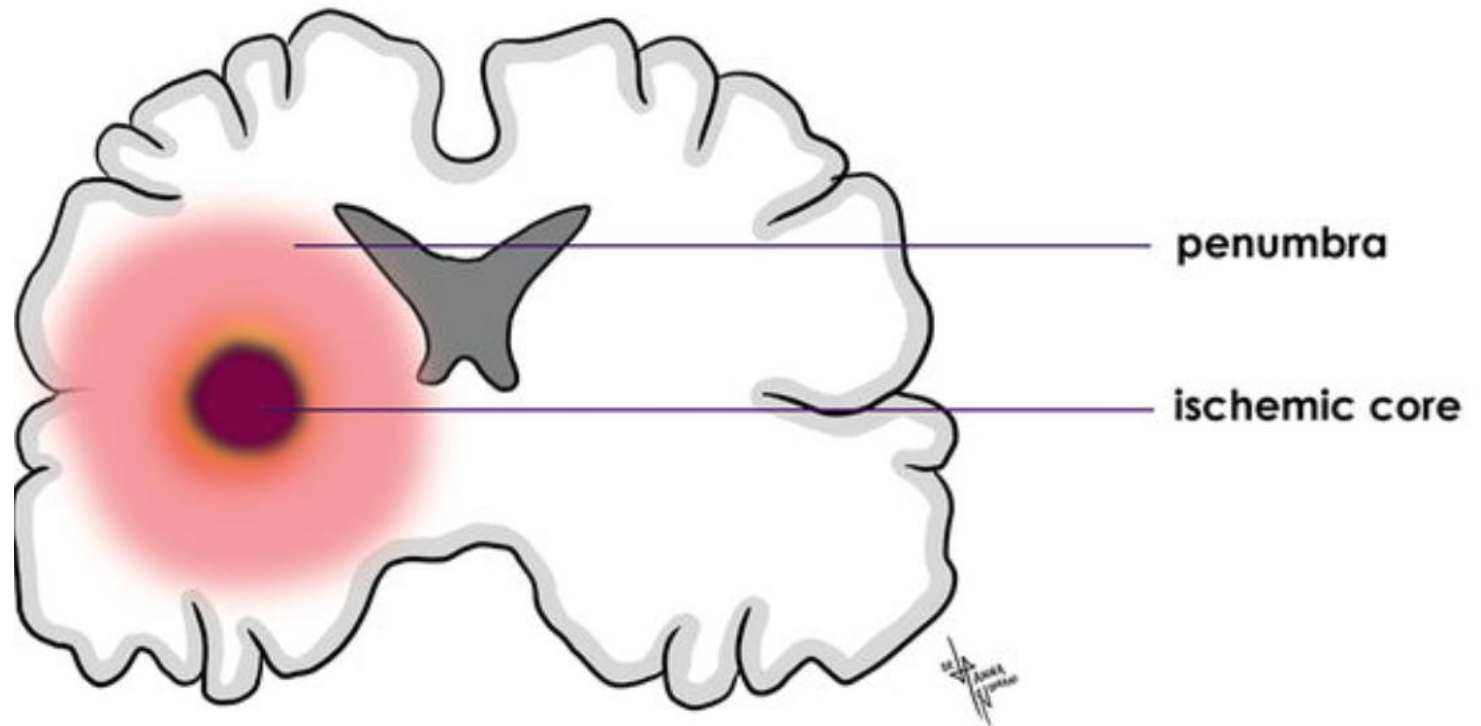
Ischemic Stroke

- 700 km axon/hour ↓
- 2 millió neuron/min ↓

Time is brain!



Ischemic Stroke

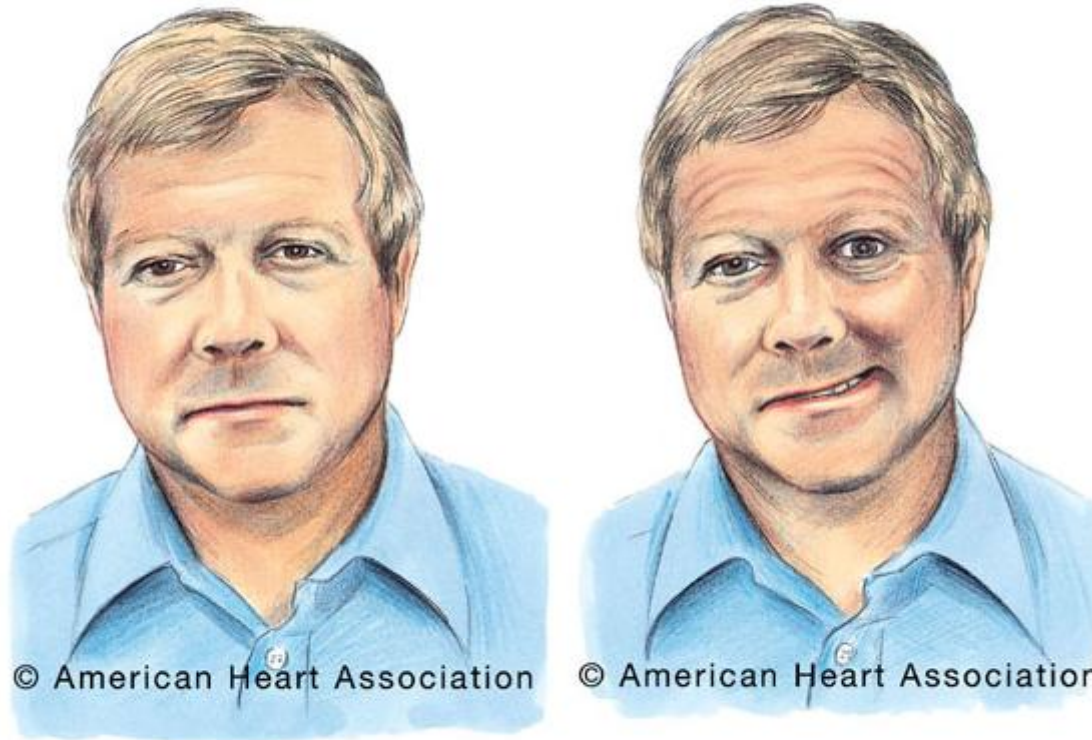


Symptoms

Cincinnati scale 1.

Cincinnati Stroke Scale

[printable version](#) PDF



Facial Droop

- *Normal*: Both sides of face move equally
- *Abnormal*: One side of face does not move at all

Cincinatti scale 2.



Arm Drift

- *Normal*: Both arms move equally or not at all
- *Abnormal*: One arm drifts compared to the other

Cincinatti scale 3.

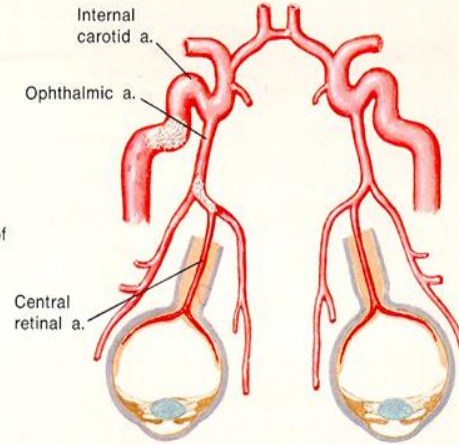
- Slurred speech, aphasia

Forebrain Ischemia (ICA/MCA)

Ischemia in Internal Carotid Artery Territory: Clinical Manifestations

A. Ocular

Transient blindness in one eye from temporary occlusion by platelet-fibrin or cholesterol emboli (on side of involved artery)



Partial blindness may be detected by covering one eye at a time to determine if defect is monocular or binocular

B. Cerebral hemisphere

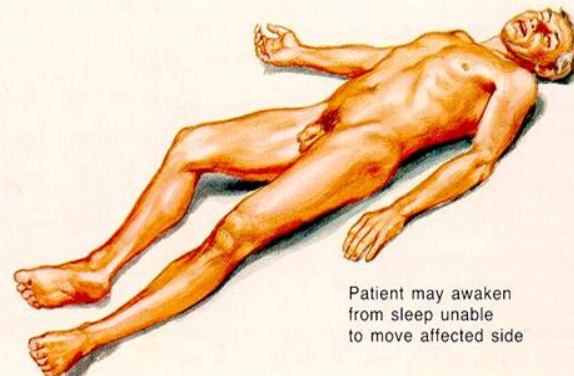
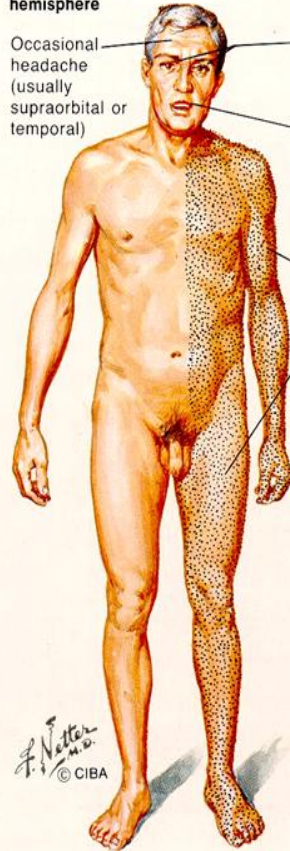Occasional headache (usually supraorbital or temporal)

Homonymous (partial) visual field defects

Language defect (partial or complete) only when dominant hemisphere is involved

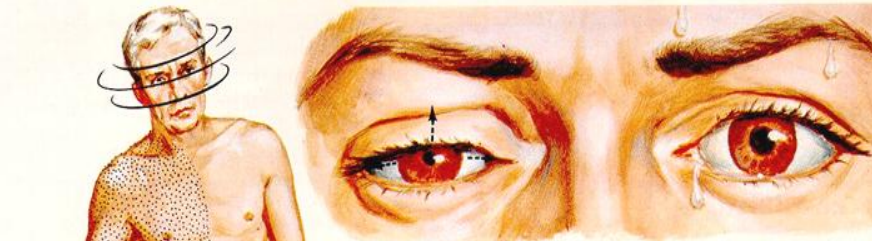
Hemiparesis or hemiplegia (only arm or leg may be affected); may be fleeting, transient or permanent and may appear with or without sensory deficits

On side opposite involved artery

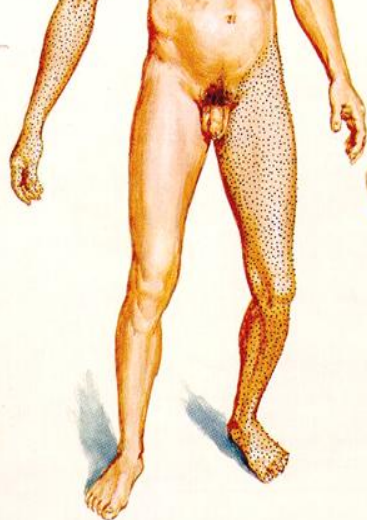

Patient may awaken from sleep unable to move affected side

F. Netter M.D.
© CIBA



Abnormal eye movements (cranial nerves III, IV and/or VI). Horner's syndrome may be present



Vertigo, ataxia; motor and sensory deficits, which may be unilateral, bilateral or alternating



Motor and sensory deficits in face; unilateral, bilateral or alternating (cranial nerves V and VII)



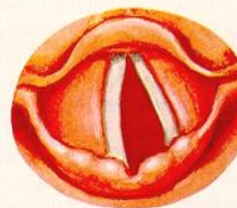Hemianopsia (frequently bilateral)



Headache, vomiting



Dysphagia (cranial nerve X)



Dysphonia (cranial nerve X)

F. Netter M.D.
© CIBA



Altered consciousness (partial or complete) may be fleeting, transient or of long duration

Vertebro
basilar

(verteb.
basilar)

TIA

(TRANSIENT ISCHEMIC ATT.)

- Transient symptoms
- Minutes
- No residual tissue deficit (MRI)

TIA is emergency!!! High risk
of devastating stroke

The neuroprotective drugs failed in acute stroke trials:

What to do?


To open the obstructed artery as soon as possible!

- with iv. thrombolysis (tissue plasminogen activator- t-PA)
- Ia. Intraarterial
- mechanical thrombectomy
- combination of them

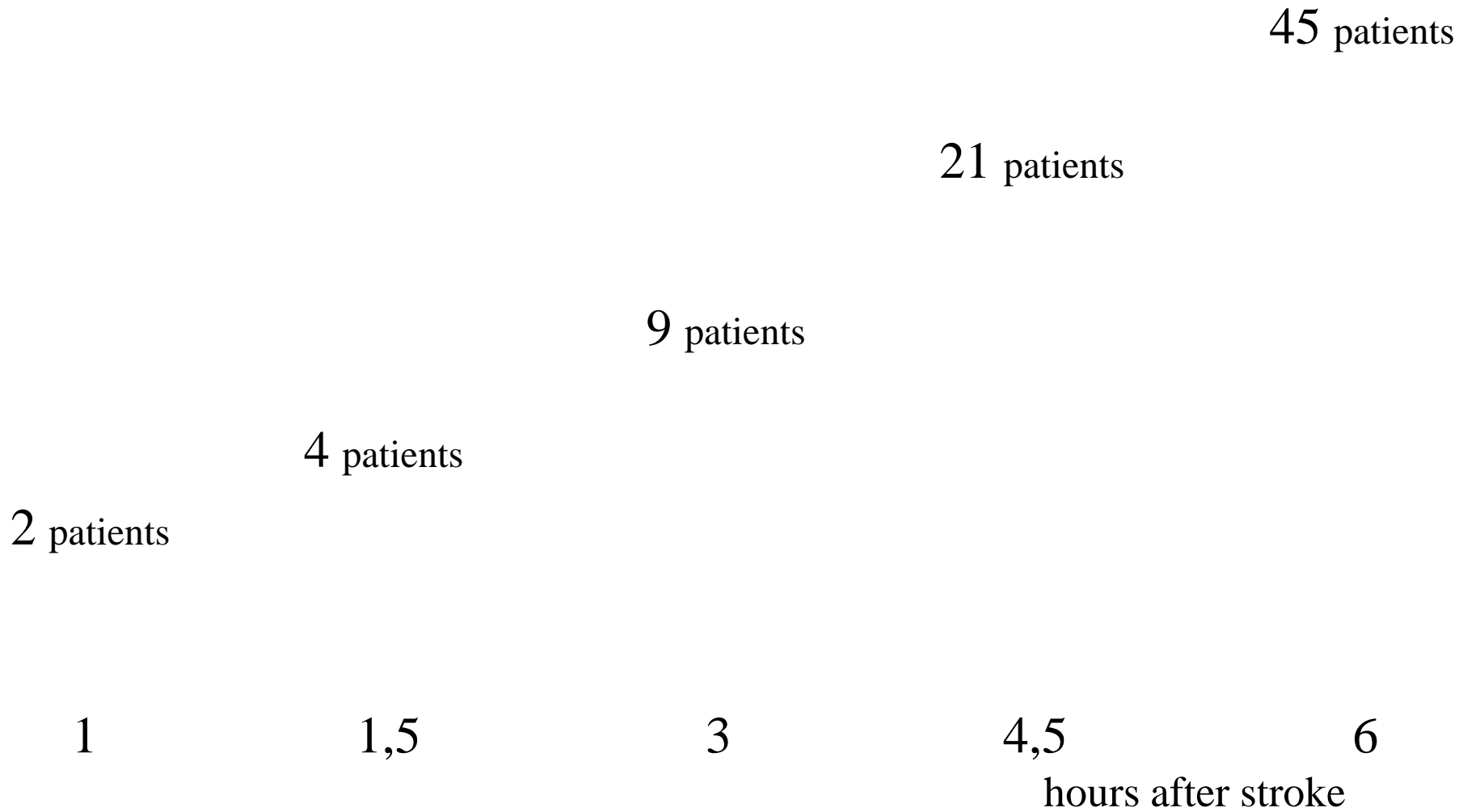
Ischemic Stroke

- 700 km axon/hour ↓
- 2 millió neuron/min ↓

Time is brain!



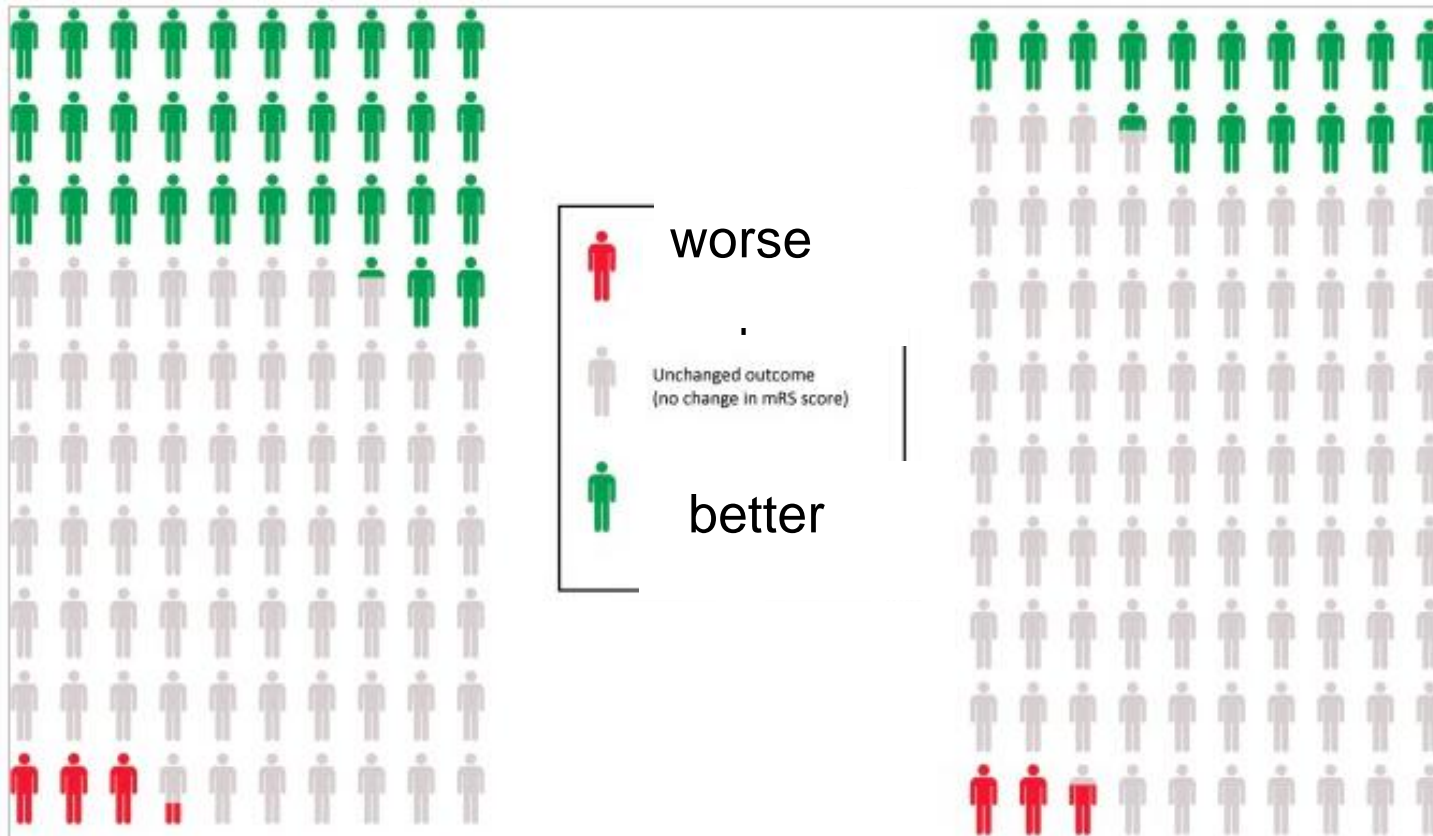
Open the artery as soon as possible



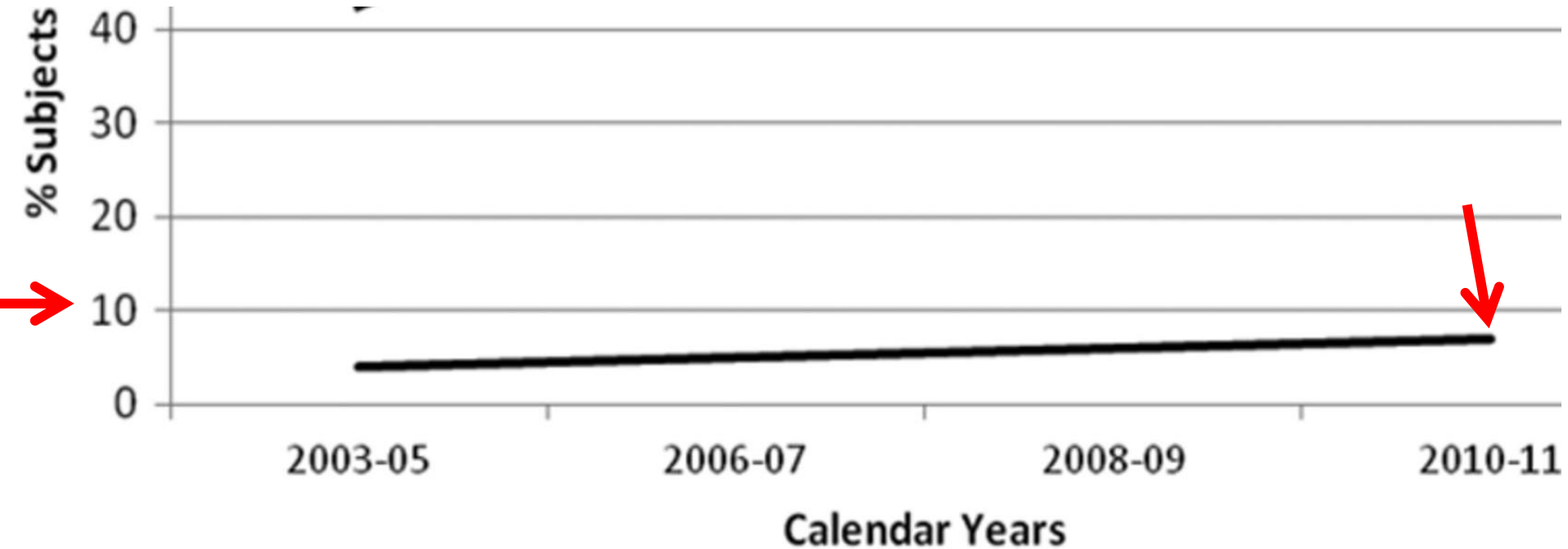
Lysis.....

Within 3 hours

between 3-4,5 hours



Lysis in acute stroke: USA

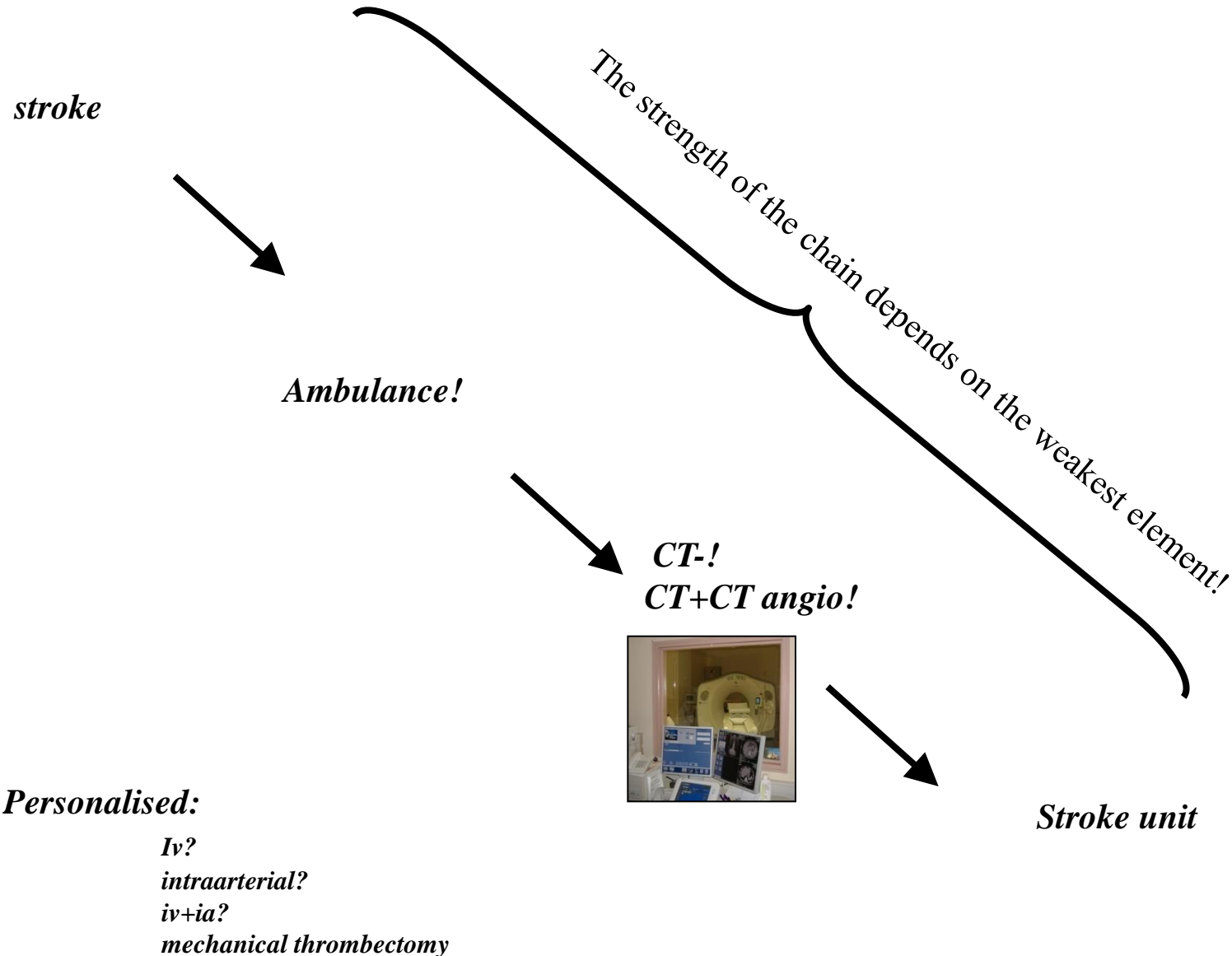


iv. Thrombolysis in Debrecen

	2011	2012	2013	2014	2015	2016.12.12.
	133	142	113	131	147	216
(%)	20	20	17	18	19%	23%

More than 1300 iv. lysis!

Debrecen stroke care



The neuroprotective drugs failed in acute stroke trials:

What to do?

To open the obstructed artery as soon as possible!

- with iv. thrombolysis (tissue plasminogen activator- t-PA)
- Ia. Intraarterial
- mechanical thrombectomy
- combination of them

The neuroprotective drugs failed in acute stroke trials:

What to do?

To open the obstructed artery as soon as possible!

- with iv. thrombolysis (tissue plasminogen activator- t-PA)
- Ia. Intraarterial
- **mechanical thrombectomy**
- combination of them

Time window?

depends on the vessel and time elapsed after stroke?

Within 4,5 hours (some subgroups 3 hours) **iv.** lysis if **small vessel** occlusion

6-8 hours **IF ICA or MCA** occlusion: **intraarterial or mechanical** thrombectomy **BUT start with iv. !!**

12 h if basilar artery occluded either **iv or ia. lysis**



time

If out of time window?

- 100-300 mg aspirin
- Monitoring of BP and ECG
- **Do NOT decrease BP till 220/110 Hgmm!**
- Pulsoximetry, 2-4 lit oxigen, if less 94%
- Normoglycemia
- LMWH or heparin to prevent **DVT** deep venous thromb.
- Nasogastric tube if dysphagia
- Antipyretic ther.
- If seizure antiepilept.
- antibiotics

After desobliteration therapy, the next
question:

cause of stroke?

Stroke: diagnosis

Imaging

- CT
- MRI
 - Diff. WI
 - TCD
- DSA angiogr.

Carotid, vertebr-

- ultrasound
- CT AG
- MRA
- DSA

ultrasound

Blood

- Blood counts
- Glucose, ions
- Coagulation?
- lipids
- Immunol. tests

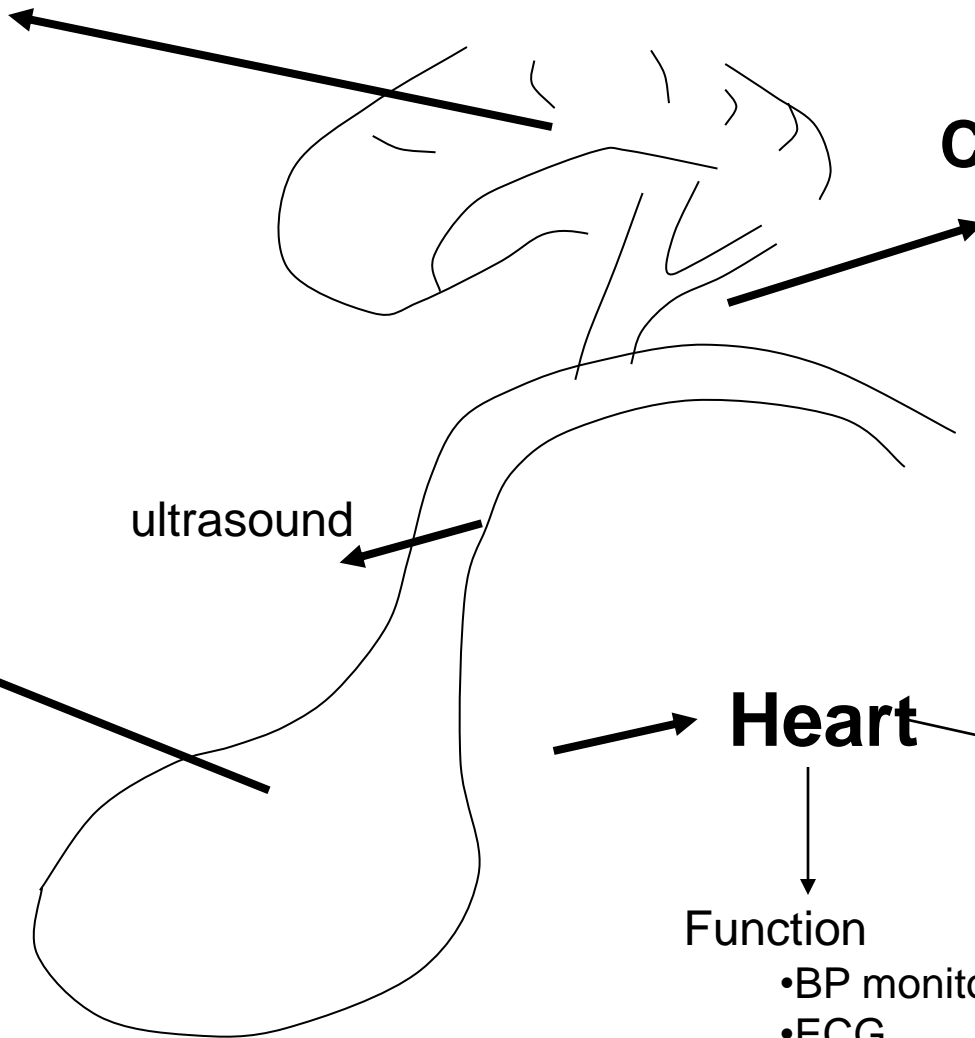
Heart

morphology

- TTE
- TEE

Function

- BP monitoring
- ECG
- Holter ECG



How to prevent the 2nd stroke?

Recurrent stroke

- 1 mo 30%
- 1 year 10%
- then 6-8%

How to prevent the 2nd stroke

1. Antiplatelet therapy

- asp+DP>aspirin mono
- clopidogrel 75 mg
- triflusal

2. Antihypertensive th.

- ACE inhib+diureticum
- E.g.perindopril+indapamide

3. Statin

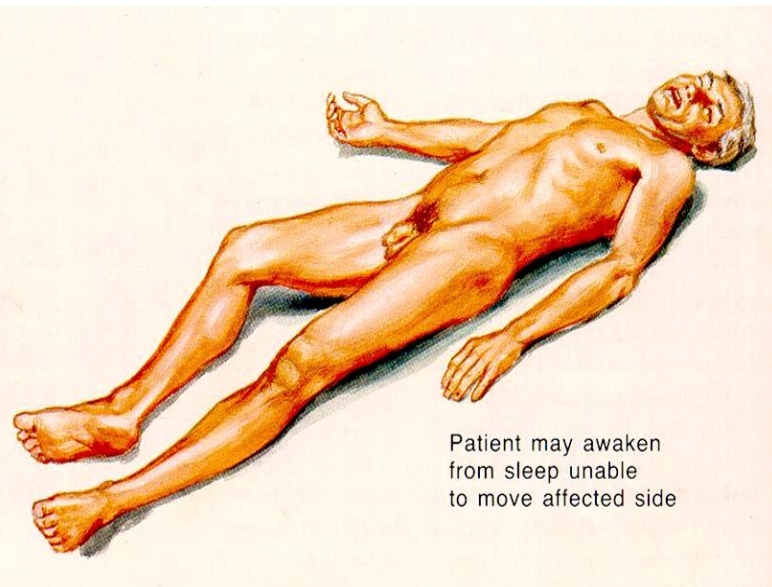
4. AF or cardiogenic source of emboli → AC INR 2-3

5. Carotid stenosis stent or CEA in 2 weeks

70-99% stenosis

Only if TIA and minor stroke

Occlusion NO!! Plegic?NO!!!!!!



Patient may awaken from sleep unable to move affected side

1. Antiplatelet

- 2x aspirin (25mg)+ ER dipyridamol (200 mg) prevents 1 pts/100 pts in 1 year
- aspirin + Clopidogrel? No!

How to prevent the 2nd stroke

1. Antiplatelet therapy

- asp+DP>aspirin mono
- clopidogrel 75 mg
- triflusal

2. Antihypertensive th.

- ACE inhib+diureticum
- E.g.perindopril+indapamide

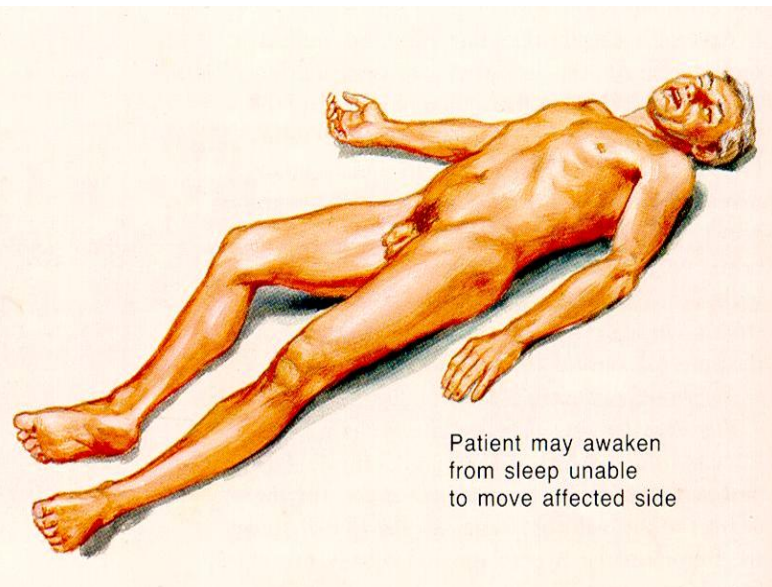
3. Statin

4. AF or cardiogenic source of emboli → AC INR 2-3

5. Carotid stenosis stent or CEA in 2 weeks

70-99% stenosis

TIA and minor stroke



Patient may awaken from sleep unable to move affected side

2. BP

- stroke risk ↑ if more than 115 Hgmm
- ↓ If 10/5 Hgmm BP stroke risk ↓ 30-40%
- Target? – 120/80 or ↓
- Diuretics alone +ACE inhib

How to prevent the 2nd stroke

1. Antiplatelet therapy

- asp+DP>aspirin mono
- clopidogrel 75 mg
- triflusal

2. Antihypertensive th.

- ACE inhib+diureticum
- E.g.perindopril+indapamide

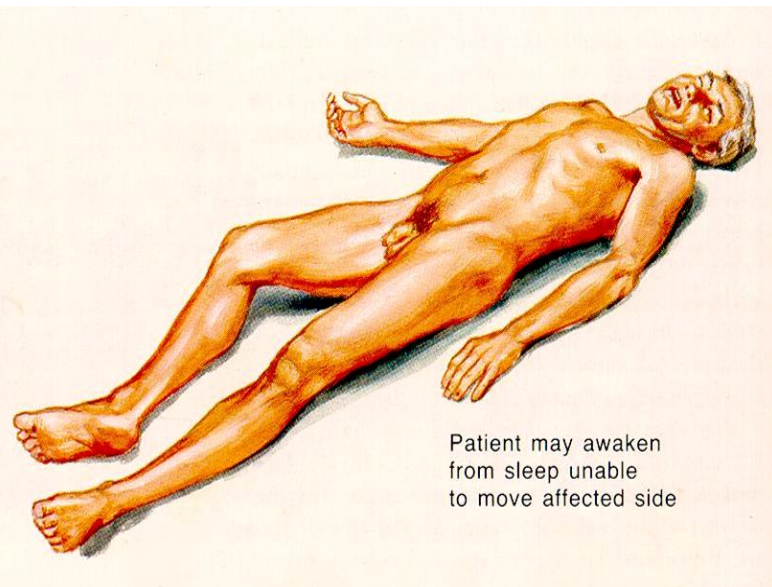
3. Statin

4. AF or cardiogenic source of emboli → AC INR 2-3

5. Carotid stenosis stent or CEA in 2 weeks

70-99% stenosis

TIA and minor stroke



3. Statin

- Statin if \geq LDL 2.6 mmol/l or signs of atherosclerosis
- target: LDL < 1.8 mmol/l
- Niacin or gemfibrosil if HDL-C low

How to prevent the 2nd stroke

1. Antiplatelet therapy

- asp+DP>aspirin mono
- clopidogrel 75 mg
- triflusal

2. Antihypertensive th.

- ACE inhib+diureticum
- E.g.perindopril+indapamide

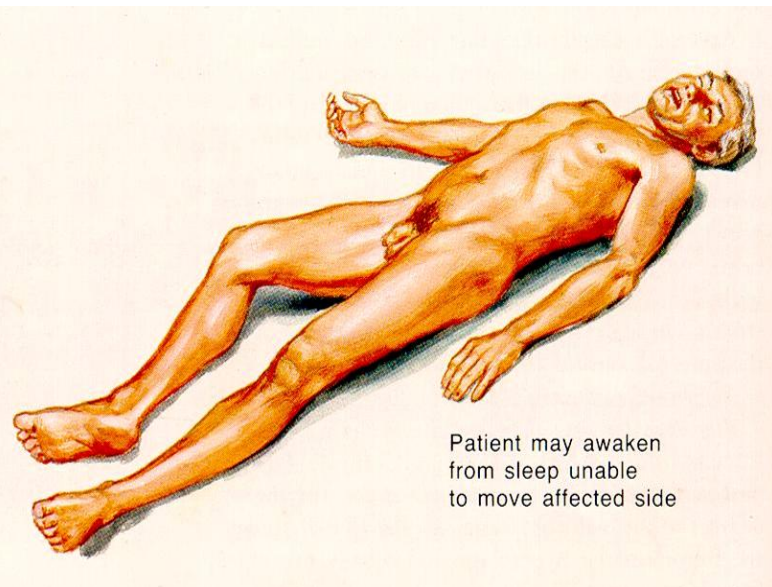
3. Statin

4. AF or cardiogenic source of emboli → AC INR 2-3

5. Carotid stenosis stent or CEA in 2 weeks

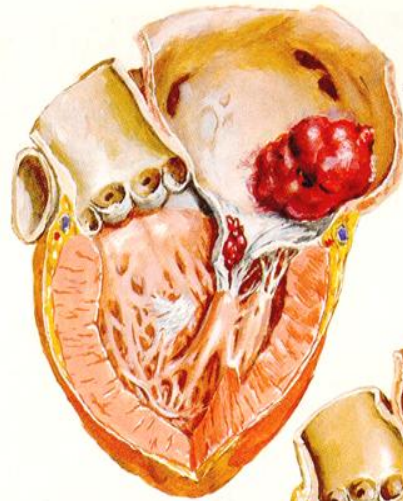
70-99% stenosis

TIA and minor stroke

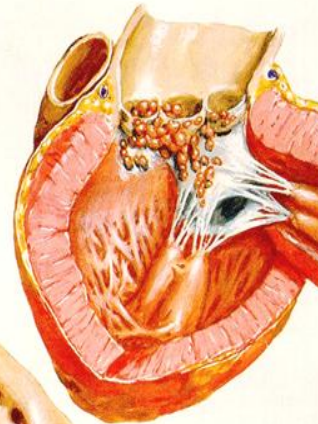


Patient may awaken from sleep unable to move affected side

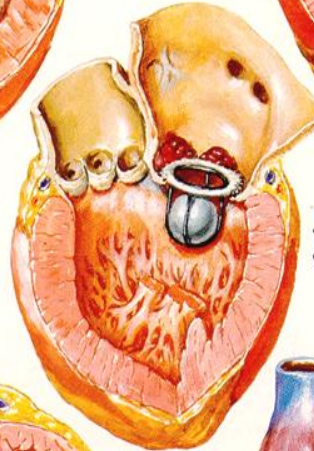
Cardiac Sources of Cerebral Emboli



Mitral stenosis, mural and valvular thrombi

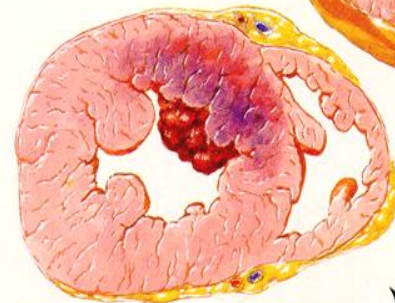

Subacute bacterial endocarditis, vegetations

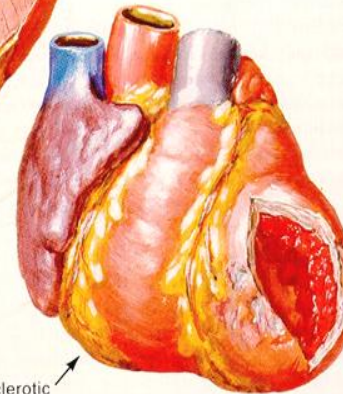

Valve replacement with thrombus formation

F. Netter M.D.
© CIBA

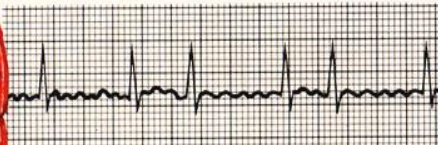
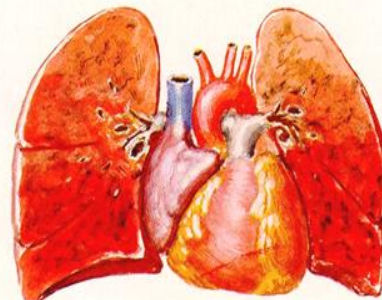


Myocardial infarction with mural thrombus



Arteriosclerotic heart disease

Ventricular aneurysm with intraluminal clot formation



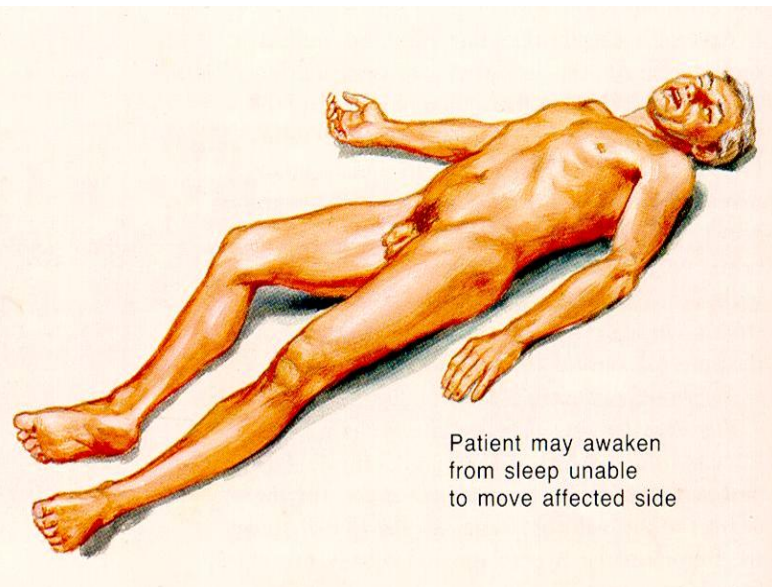
Congestive heart failure, atrial fibrillation

4. If AF post-stroke

- Aspirin is NOT enough---if possible -----AC with
 - warfarin
 - or NOAC (dabigatran, rivaroxaban, apixaban, edoxaban----all as good as warfarin but less bleeding and no need for INR control)

How to prevent the 2nd stroke

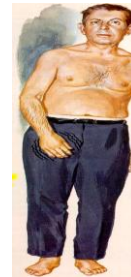1. Antiplatelet therapy
 - asp+DP > aspirin mono
 - clopidogrel 75 mg
 - triflusal
2. Antihypertensive th.
 - ACE inhib+diureticum
 - E.g. perindopril+indapamide
3. Statin
4. AF or cardiogenic source of emboli → AC INR 2-3
5. Carotid stenosis stent or CEA in 2 weeks
 - 70-99% stenosis
 - TIA and minor stroke



Patient may awaken from sleep unable to move affected side

Carotid Stent or CEA after TIA or minor stroke

If
Periprocedural
stroke+mort.
<6%



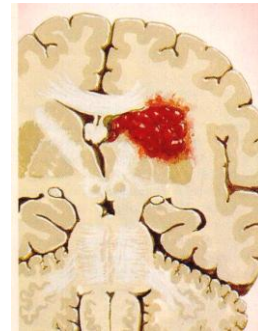
>70 y CEA>CAS



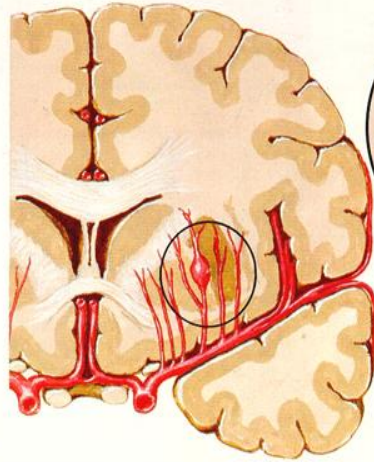
<70 év

BUT! Analyse the carotid plaque!!!!

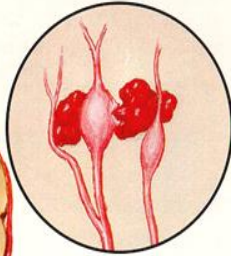sp. Hemorrhage 10-15%



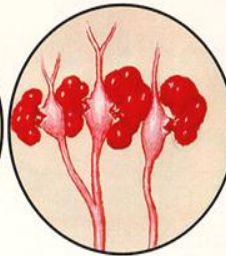
Intracerebral Hemorrhage (Hypertensive): Pathogenesis



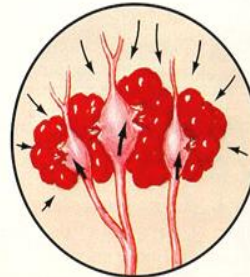A. Microaneurysm formed in parenchymal artery of brain as result of hypertension. Lenticulostriate vessels (shown) most commonly involved, but similar process may occur in other parts of brain, especially lobar white matter, thalamus, pons and cerebellum



B. Microaneurysm ruptures, causing pressure on adjacent (satellite) vessels

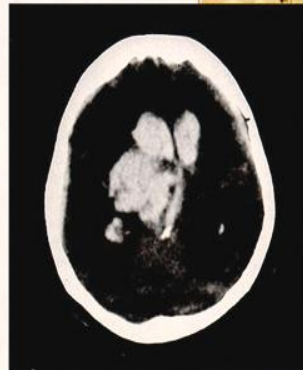
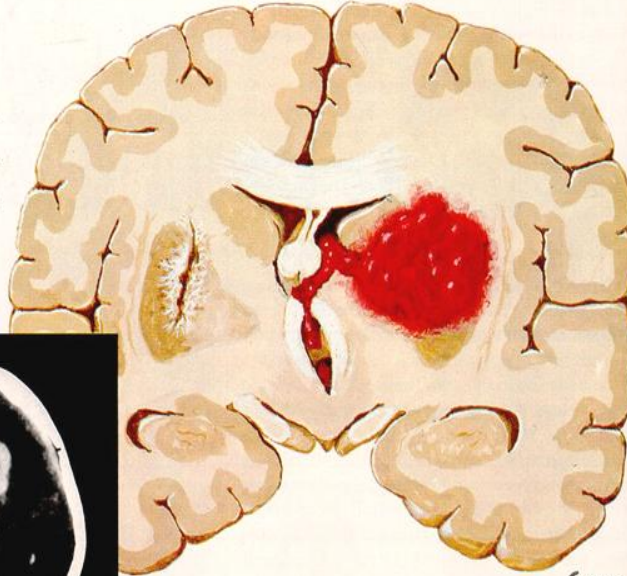


C. Satellite vessels rupture




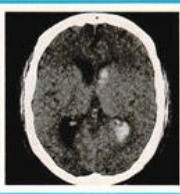

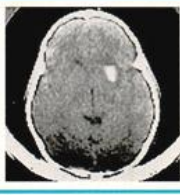

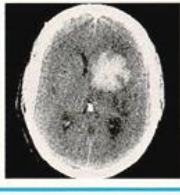

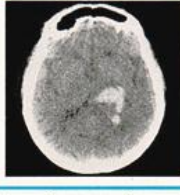

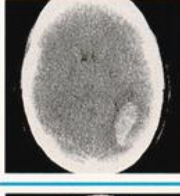

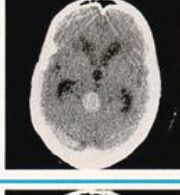


D. Amount of blood extravasated into brain tissue depends on tissue turgor opposed to intravascular blood pressure

Moderate-sized intracerebral hemorrhage involving left putamen, with rupture into lateral ventricle. Brain distorted to opposite side. Scar of healed hemorrhage on right side



CT scan showing large putaminal hemorrhage with blood in ventricles

F. Netter M.D.
© CIBA

	Pathology	CT scan	Pupils	Eye movements	Motor and sensory deficits	Other
Caudate nucleus (blood in ventricle)			Sometimes ipsilaterally constricted	Conjugate deviation to side of lesion. Slight ptosis	Contralateral hemiparesis, often transient	Headache, confusion
Putamen (small hemorrhage)			Normal	Conjugate deviation to side of lesion	Contralateral hemiparesis and hemisensory loss	Aphasia (if lesion on left side)
Putamen (large hemorrhage)			In presence of herniation, pupil dilated on side of lesion	Conjugate deviation to side of lesion	Contralateral hemiparesis and hemisensory loss	Decreased consciousness
Thalamus			Constricted, poorly reactive to light bilaterally	Both lids retracted. Eyes positioned downward and medially. Cannot look upward	Slight contralateral hemiparesis, but greater hemisensory loss	Aphasia (if lesion on left side)
Occipital lobar white matter			Normal	Normal	Mild, transient hemiparesis	Contralateral hemianopsia
Pons			Constricted, reactive to light	No horizontal movements. Vertical movements preserved	Quadriplegia	Coma
Cerebellum			Slight constriction on side of lesion	Slight deviation to opposite side. Movements toward side of lesion impaired, or sixth cranial nerve palsy	Ipsilateral limb ataxia. No hemiparesis	Gait ataxia, vomiting

F. Netter M.D.
© CIBA

ICH

- neuroimaging with CT or MRI
- CT angiography and contrast CT may be considered to identify patients at risk for hematoma expansion
 - structural lesions?
 - vascular malformations?
 - tumors?

VII

- FVIIa can limit the extent of hematoma expansion
- increase in thromboembolic risk with rFVIIa
- rFVIIa is not recommended
- intermittent pneumatic compression +elastic stockings
- *After cessation of bleeding, low-dose sc. LMW heparin or unfractionated heparin may be considered for prevention of DVT with lack of mobility after 1 to 4 days from onset!!!!*

Guidelines for the Management of Spontaneous Intracerebral Hemorrhage ASA/AHA 2015

Blood Pressure	<u>For ICH patients presenting with SBP between 150 and 220 mm Hg and without contraindication to acute BP treatment, acute lowering of SBP to 140 mm Hg is safe (Class I; Level of Evidence A) and can be effective for improving functional outcome (Class IIa; Level of Evidence B). (Revised from the previous guideline)</u>
General Monitoring and Nursing Care	<u>Initial monitoring and management of ICH patients should take place in an intensive care unit or dedicated stroke unit with physician and nursing neuroscience acute care expertise (Class I; Level of Evidence B). (Revised from the previous guideline)</u>

Intravenous Medications That May Be Considered for Control of Elevated Blood Pressure in Patients with ICH

Drug	Intravenous Bolus Dose	Continuous Infusion Rate
Labetalol	5 to 20 mg every 15 min	2 mg/min (maximum 300 mg/d)
Nicardipine	NA	5 to 15 mg/h
Esmolol	250 µg/kg IVP loading dose	25 to 300 µg · kg ⁻¹ · min ⁻¹
Enalapril	1.25 to 5 mg IVP every 6 h*	NA
Hydralazine	5 to 20 mg IVP every 30 min	1.5 to 5 µg · kg ⁻¹ · min ⁻¹
Nipride	NA	0.1 to 10 µg · kg ⁻¹ · min ⁻¹
Nitroglycerin	NA	20 to 400 µg/min

Prevention of Secondary Brain Injury

- Glucose should be monitored and normoglycemia (range 4.4 to 6,1 mmol/L)
- seizures should be treated with antiepileptic drugs
- Prophylactic anticonvulsant medication should not be used

Surgery

- If Glasgow Coma Scale of 8 +clinical evidence of transtentorial herniation,
- or significant intraventric. Hemorrhage (IVH)
- or hydrocephalus
- ventricular drainage in patients with decreased level of consciousness

Surgery 2

- uncertain
- exceptions deteriorating cerebellar hemorrhage
 - with brainstem compression
 - and/or hydrocephalus ASAP!

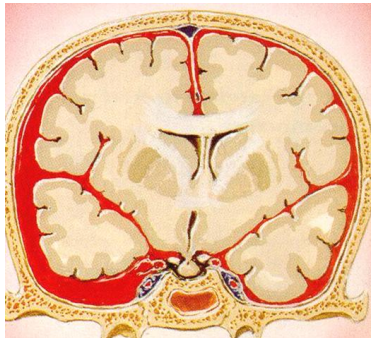
Clot removal

- lobar clots **>30 ml and within 1 cm** of the surface, by standard craniotomy **might be considered**
- The effectiveness
 - of minimally invasive clot evacuation
 - stereotactic
 - or endoscopic aspiration with or without thrombolytic usage is uncertain
 - no clear evidence

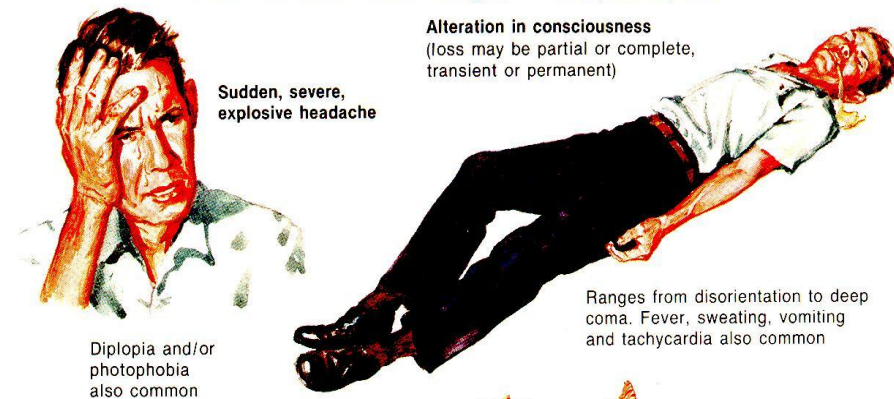
Prevention of Recurrent ICH

- risk factors for recurrence:
 - Lobar location
 - older age,
 - ongoing anticoagulation,
 - presence of the apolipoprotein E $\epsilon 2$ or $\epsilon 4$ alleles,
 - and greater number of microbleeds on MRI!!
- After the acute ICH period BP <140/90
<130/80 if diabetes or chronic kidney disease,
reasonable

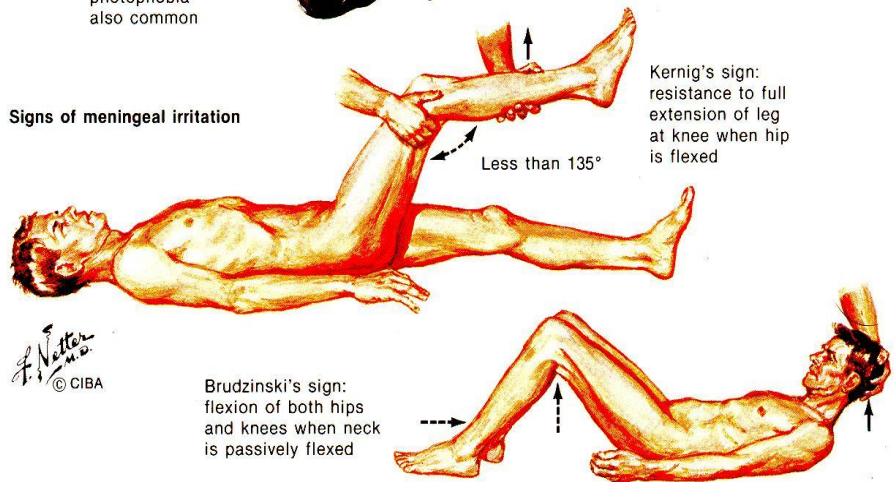
Subarachnoid bleeding



Clinical Manifestations of Congenital Aneurysm Rupture

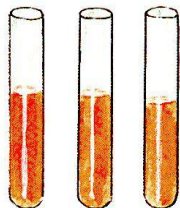


Signs of meningeal irritation

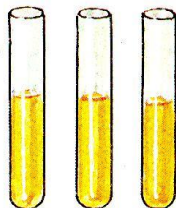


Cerebrospinal fluid


Three successive fluid samples collected. Shortly after or during bleeding, all 3 samples frankly bloody or orange



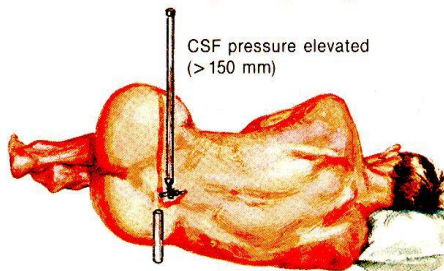
Later, on repeat tap, all 3 samples are xanthochromic (yellow) as a result of hemoglobin release or bilirubin formation



If blood is due to traumatic tap, fluid clears progressively in successive samples



CSF pressure elevated (> 150 mm)



SAH

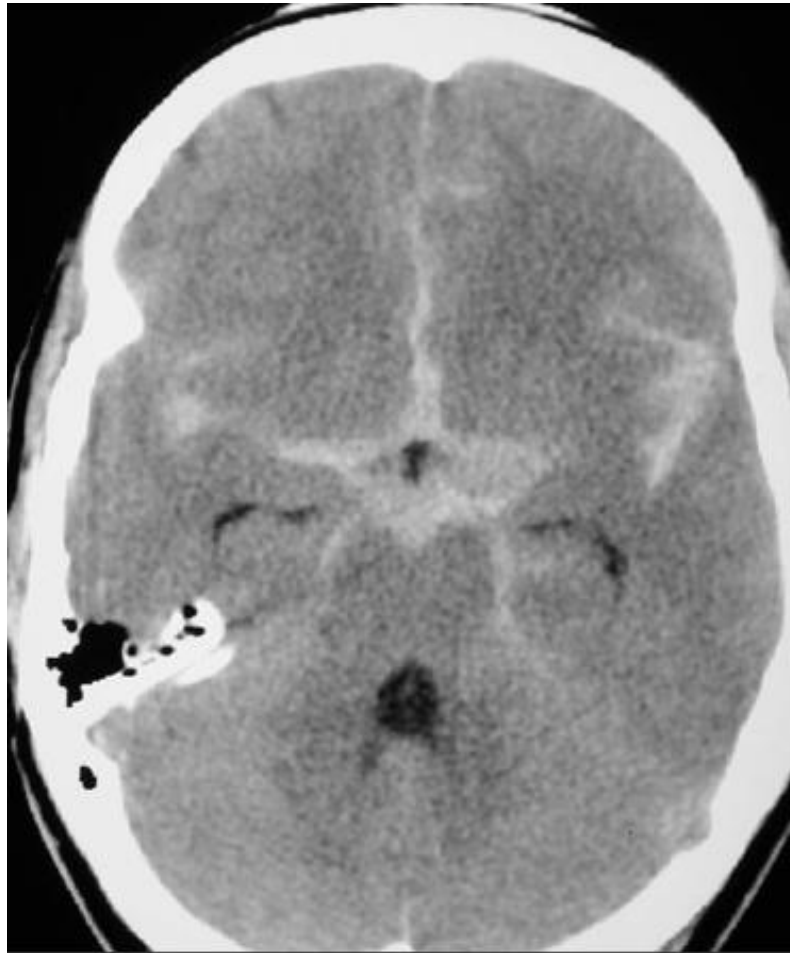10-20/100 000

- Thunderclap headache
 - Vomitus, photophobia
 - During physical exercise
- But not always!**

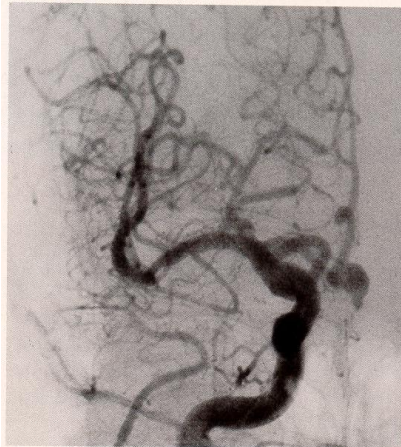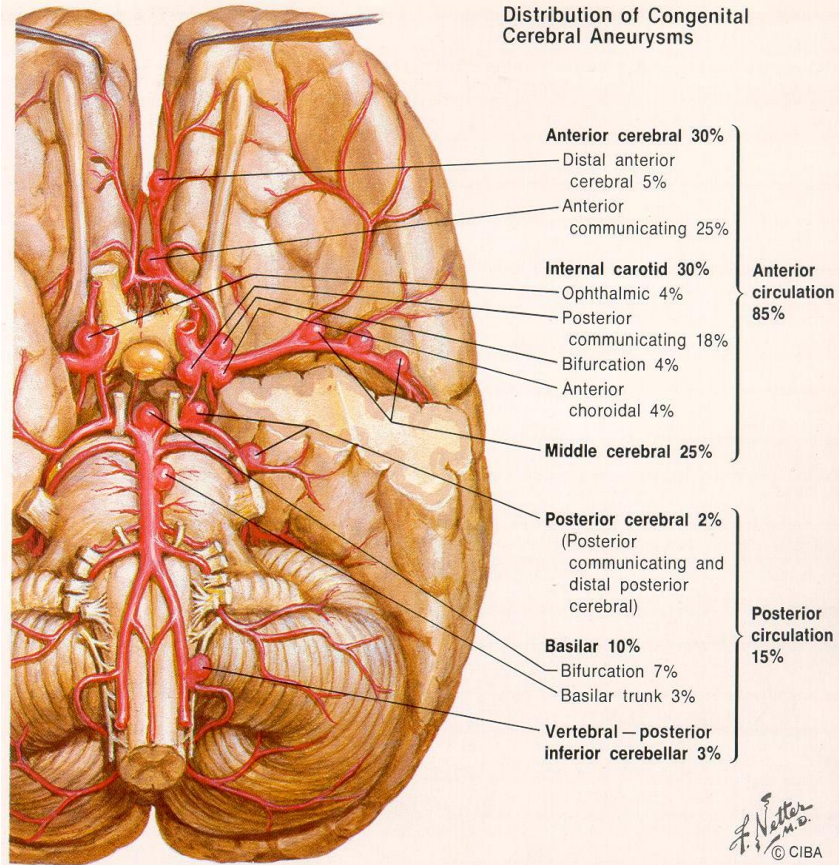
- Neck rigidity
- sometimes paresis

ACT sometimes negative!! **Lp!**
aneurysma multiplex?
Vasospasm 4-11 day

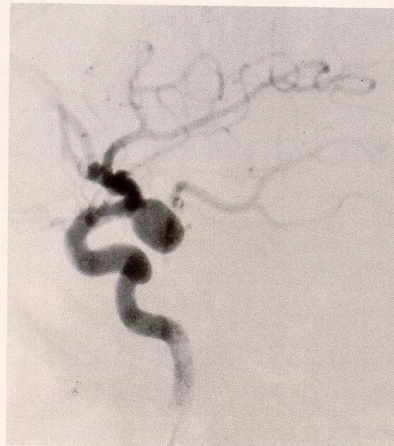
SAH



Distribution of Congenital Cerebral Aneurysms

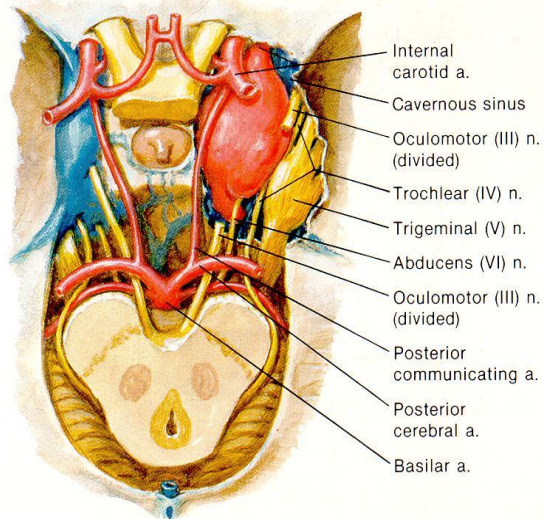


Frontal carotid arteriogram disclosing bilobate aneurysm of anterior communicating artery

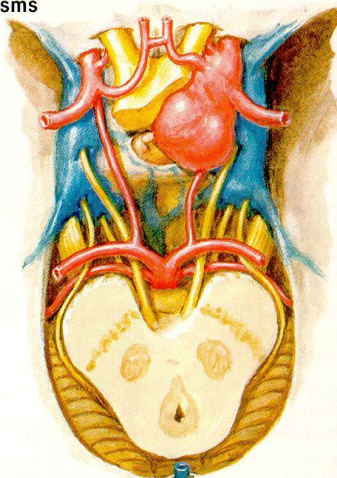


Different patient: lateral view showing large aneurysm of internal carotid artery at origin of posterior communicating artery

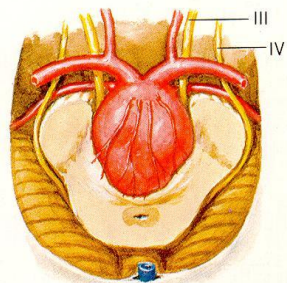
Giant Congenital Aneurysms



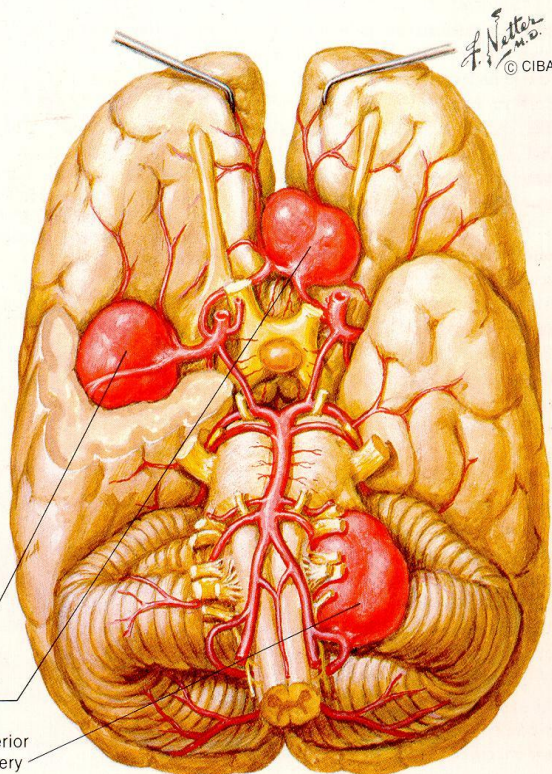
A. Intracavernous (intraclinoïd) internal carotid aneurysm compressing abducens (VI) nerve. Oculomotor (III), trochlear (IV) and trigeminal (V) nerves may also be affected. Trigeminal involvement may cause facial pain



B. Aneurysm of supraclinoid segment of internal carotid artery elevating optic chiasm, distorting infundibulum and compressing oculomotor (III) nerve



C. Aneurysm of basilar bifurcation projecting posteriorly, invading peduncles and compressing cerebral aqueduct. Corticospinal tracts may be affected, resulting in paralysis or paresis



D. Aneurysm of middle cerebral artery

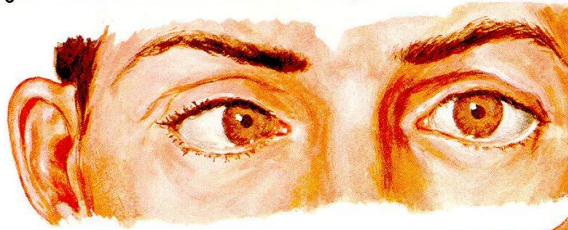E. Aneurysm of anterior cerebral-anterior communicating arteries

F. Aneurysm of posterior inferior cerebellar artery

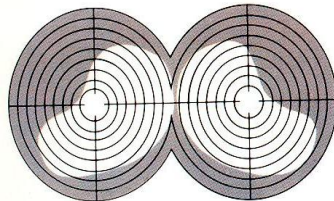
Ophthalmologic Manifestations of Cerebral Aneurysms

A. Neuromuscular disorders

Abducens nerve palsy: affected eye turns medially. May be first manifestation of intracavernous carotid aneurysm. Pain above eye or on side of face may be secondary to trigeminal (V) nerve involvement

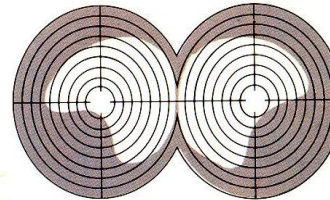


Oculomotor nerve palsy: ptosis, eye turns laterally and inferiorly, pupil dilated. Common finding with cerebral aneurysms, especially carotid-posterior communicating aneurysms

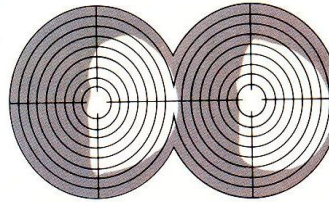


Superior bitemporal quadrantanopia caused by supraclinoid carotid aneurysm compressing optic chiasm from below

B. Visual field disturbances



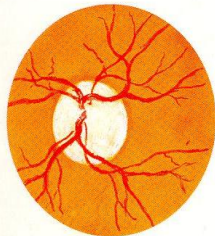
Inferior bitemporal quadrantanopia caused by compression of optic chiasm from above



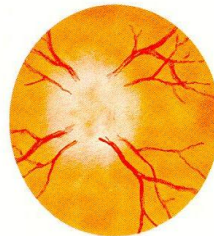
Right (or left) homonymous hemianopia caused by compression of optic tract. Unilateral amaurosis may occur if optic (II) nerve is compressed

F. Netter M.D.
© CIBA

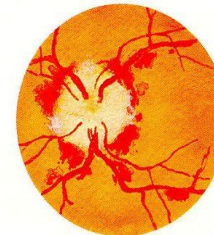C. Retinal changes



Optic atrophy may develop as result of pressure on optic (II) nerve from a supraclinoid carotid, ophthalmic or anterior cerebral aneurysm



Papilledema may be caused by increased intracranial pressure secondary to rupture of cerebral aneurysm



Hemorrhage into optic (II) nerve sheath after rupture of aneurysm may result in subhyaloid hemorrhage, with blood around disc

HUNT AND HESS SCALE.

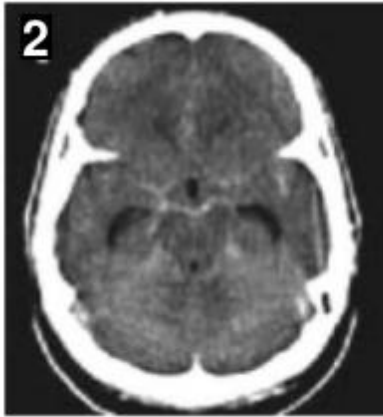I - Asymptomatic or with mild headache

II-Moderate or severe headache, nuchal rigidity

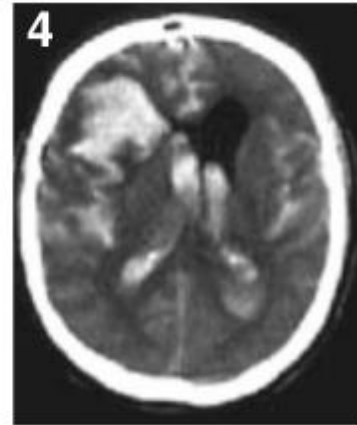
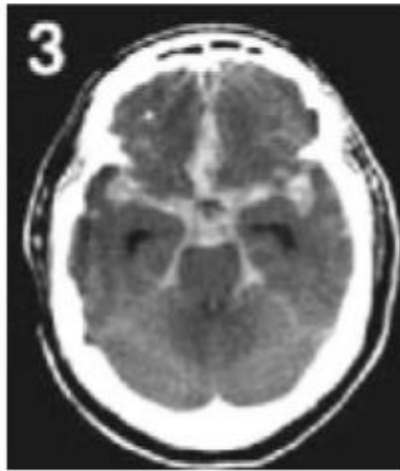
III-Confusion, drowsiness, or mild focal deficit
(discounting third nerve palsy)

IV-Stupor or hemiparesis, early decerebrate
rigidity

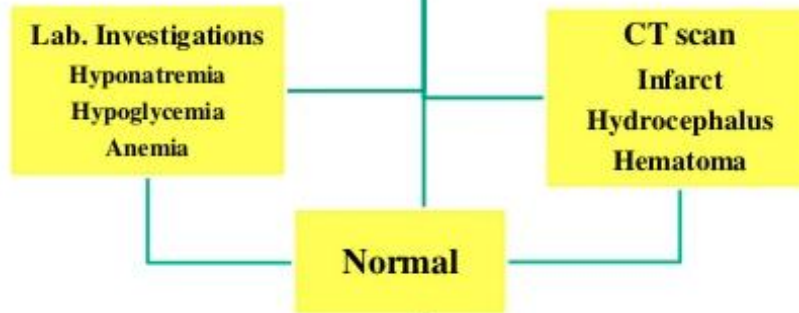
V-Deep coma, extensor posturing



Fisher's Grade



Clinical vasospasm



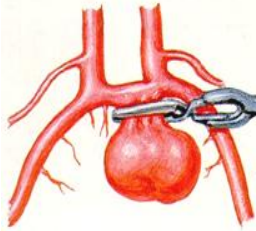
Vasospasm management

Euvolemia

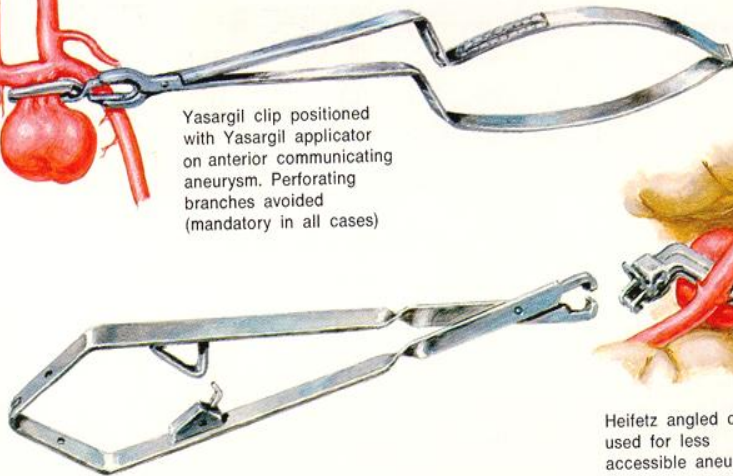
Induction of hypertension

DSA and intra-arterial nimodipine OR angioplasty

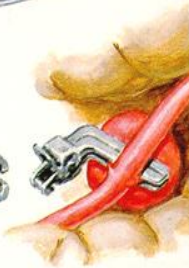Aneurysm Clips



Yasargil clip positioned with Yasargil applicator on anterior communicating aneurysm. Perforating branches avoided (mandatory in all cases)

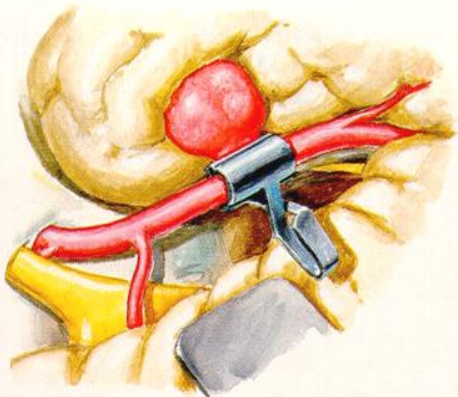
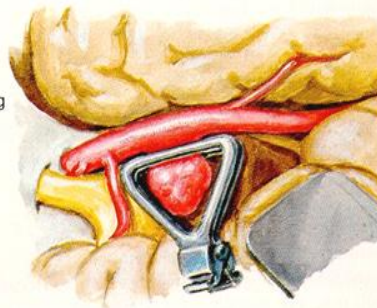


Heifetz applicator

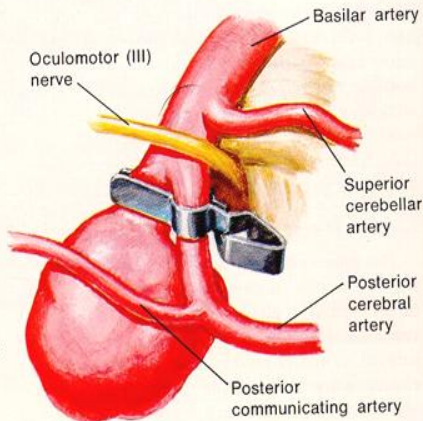


Heifetz angled clip used for less accessible aneurysm

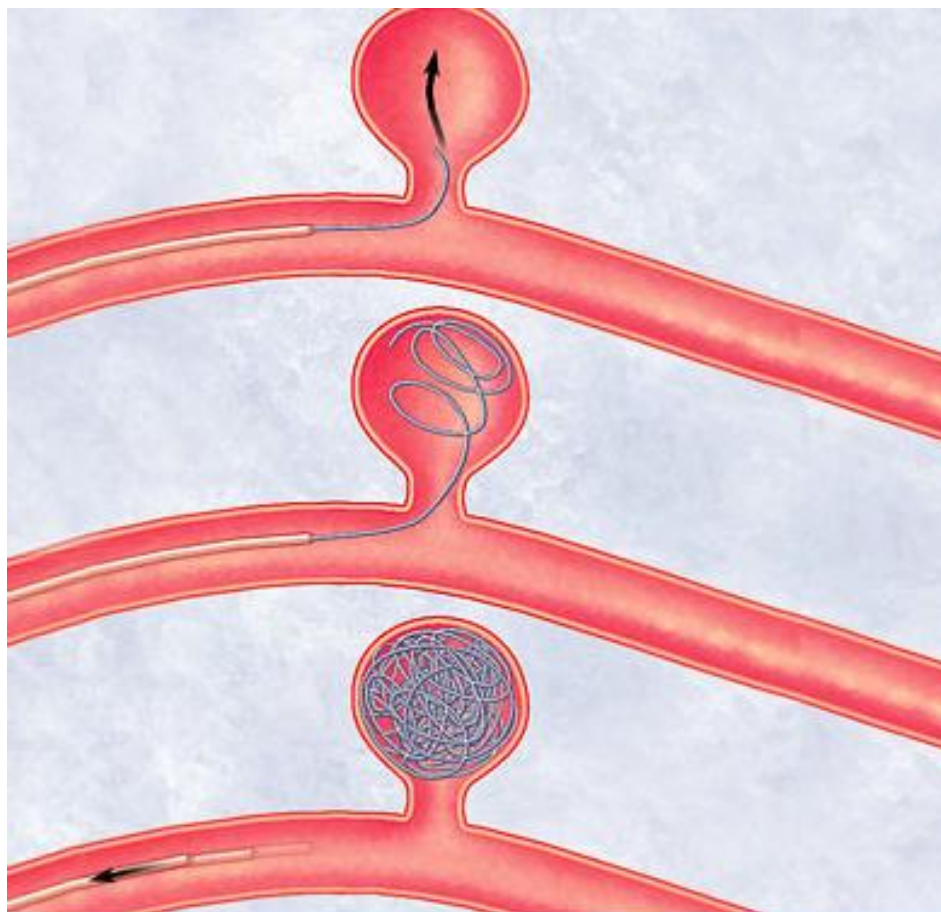
Heifetz encompassing clip applied



Sundt encircling clip used to occlude aneurysm neck on opposite side of vessel



Drake clip encircling posterior cerebral artery to occlude neck of basilar bifurcation aneurysm



© Mayo Foundation for Medical Education and Research. All rights reserved.

Therapy

- Anti-HT (eg, IV beta block.) if mean BP more than 130
- **No Nitrite!**
- Hydralazine and calcium calcium blocker
- ACE
- Intubation hiperventilation
- Mannisol
- furosemide
- IV steroid (contradict.)

Complications

- Re-bleeding
- Vasospasm (4-11. nap, Transcran Doppler)
nimodipine
- Hydrocephalus
- Hyponatremia
- Seizures
- Lung edema, MI